

## Short and long implants to restore an atrophic posterior maxilla

Francesco Amato, MD, DDS, PhD<sup>1</sup>, Italy

The 62-year-old male patient presented with missing teeth in the left posterior maxilla. Clinical and radiographic examination revealed the presence of sufficient vertical and horizontal bone height to enable placement of a long implant in the first premolar region and adequate width, but insufficient height, in the first molar region. A treatment plan was developed that called for a standard length implant in the premolar region and a short implant in the molar site. The implants were submerged for 6 months of healing. A definitive three-unit bridge was then delivered.

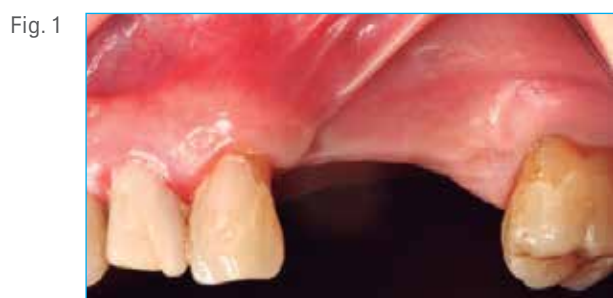

Fig. 1 Preoperative clinical photograph showing the missing premolars and first molar.

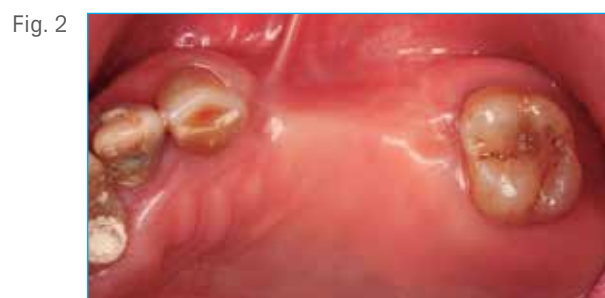

Fig. 2 Occlusal view, note the buccal concavity in the edentulous area.

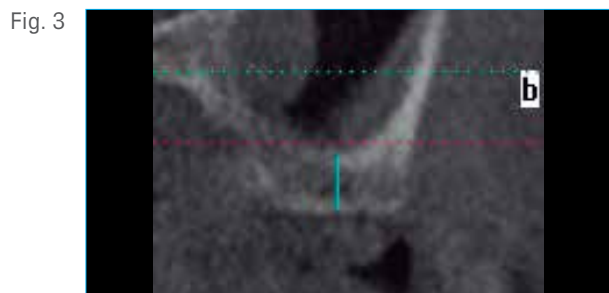


Fig. 3 TAC image of the remaining bone height in the molar region 3 mm.

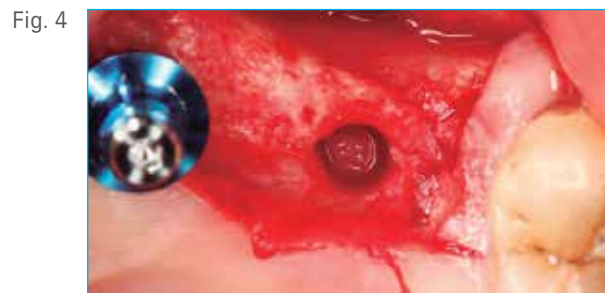

Fig. 4 Insertion of a T3® Tapered Implant 4 mm D x 11.5 mm L in the first premolar region. Osteotomy preparation was performed with a small drill and a convex osteotome to push the cortical bone into the sinus cavity.

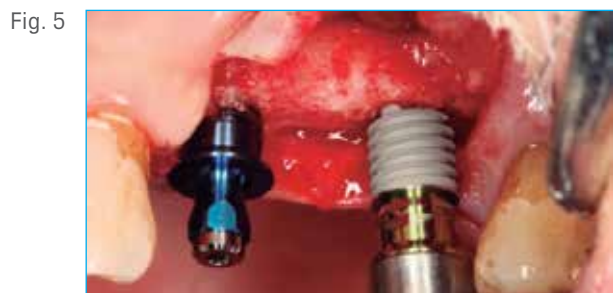

Fig. 5 Insertion of a T3 Short Implant 5 mm D x 6 mm L in the molar region.

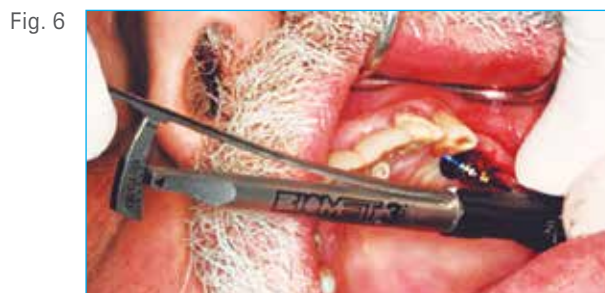

Fig. 6 Hand ratcheting the implant to its final position. Final seating torque reading: 70 Ncm.

Clinical Case

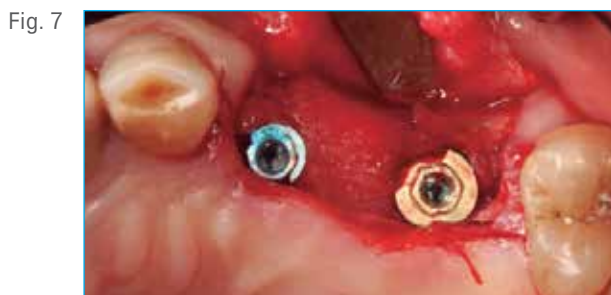

Fig. 7  
Occlusal view of the two implants in place before healing abutment placement and proceeding to flap closure.

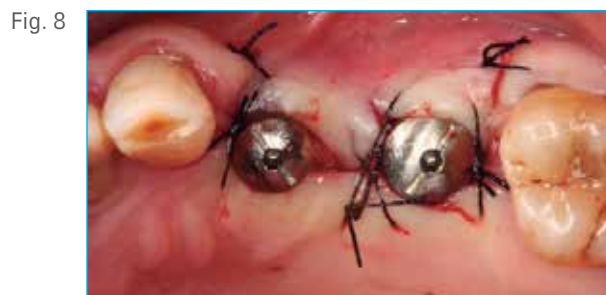

Fig. 8  
Flap closure around the healing abutments following the Palacci technique to increase the thickness of the buccal gingiva.

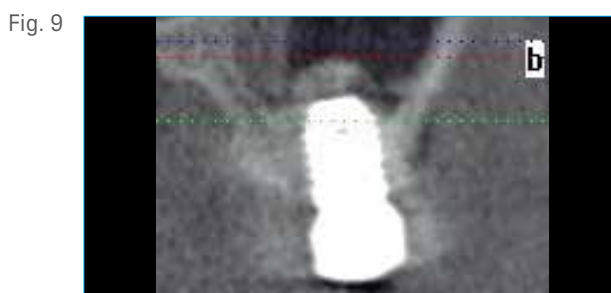


Fig. 9  
Radiograph of the T3 Short Implant just placed in the molar site with a manually platform switched healing abutment (4.1 mm diameter platform on the 5 mm diameter platform implant).

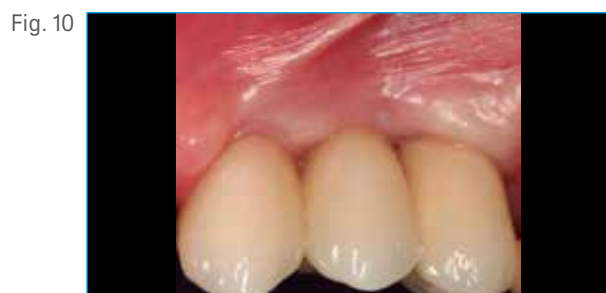

Fig. 10  
A three-unit screw-retained porcelain-fused-to-metal bridge was placed 6 months post-implant placement.

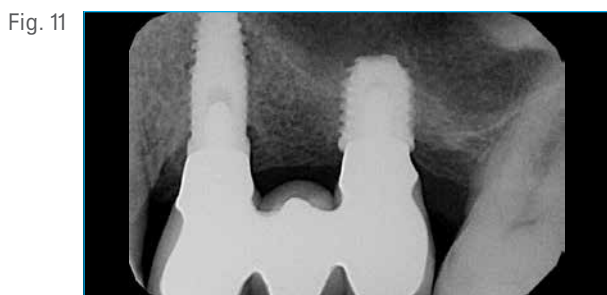

Fig. 11  
Control radiograph 6 months post-op. Note the consolidation of the bone around the apex of the T3 Short Implant.

Francesco Amato, MD, DDS, PhD<sup>†</sup>



Dr. Francesco Amato completed his MD degree at the University of Catania, Italy in 1991. In 1992–1993 he completed a one year full time Advanced Program for International Dentists in Periodontics at New York University College of Dentistry followed by two years full time Advanced Program for International Dentists in Implant Dentistry at New York University College of Dentistry, 1993–1995. He completed his continuing Education Program in Implant Dentistry at New York University College of Dentistry, 1994–1995. He received his Ph.D. Biopharmaceutical Microbiology at the University of Catania, Italy, 1994–1997. He has published numerous articles in international journals; is a lecturer in National and International Conferences and Courses. He is in private practice specializing in Periodontics and Implant Dentistry in Catania, Italy, and is a Clinical Professor in the Master of Periodontology at Universitat Internacional de Catalunya, Spain, a Visiting Professor in the Department of Periodontology at Columbia University, New York, and an International lecturer for the Continuing Dental Education at New York University, New York.

<sup>†</sup>The contributing clinician has a financial relationship with Zimmer Biomet Dental resulting from speaking engagements, consulting engagements, and other retained services.