

Restoration of a resorbed mandibular left posterior quadrant with short and long implants

Francisco J. Enrile de Rojas, MD, DDS¹, Spain

The 70-year-old female was missing the mandibular posterior teeth in both quadrants. The clinical and radiographic studies revealed very little bone height, only 6 mm in the molar region of the mandibular right posterior quadrant with sufficient ridge width for a short, wide implant. The bone appeared dense and the gingiva thin and non-keratinized, in some areas as thin as 1 mm. The mandibular left quadrant had sufficient bone height for standard length implants. The treatment for the mandibular right quadrant consisted of placement of two short implants in tooth positions 29 and 30 [45 and 46] and a longer implant in tooth position 28 [44] using a conservative two-stage approach. Due to the advanced age and medical conditions of the patient it was decided to not do a connective tissue graft.

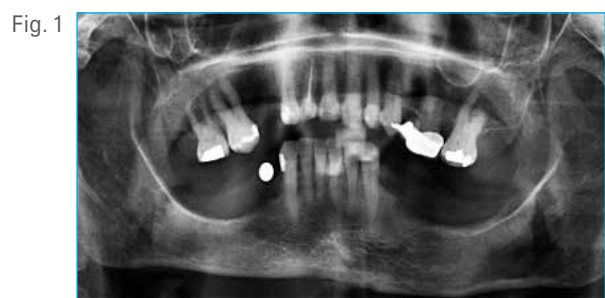

Fig. 1 Preoperative radiograph: Observe the very little bone height above the mental nerve in the mandibular right posterior quadrant.

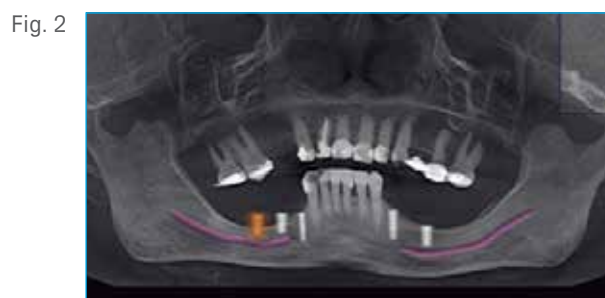

Fig. 2 Case planification with the Cone Bean CT scan. Only 6 mm bone height in the second premolar and first molar regions above the mental nerve.

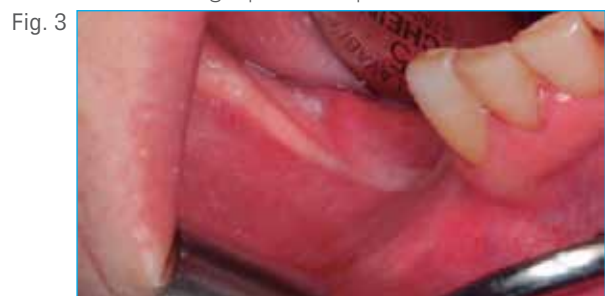

Fig. 3 Preoperative view.

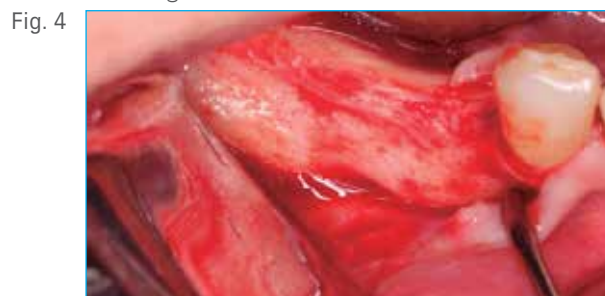

Fig. 4 Sufficient bone width for 5 and 6 mm diameter implants in the second premolar and first molar regions.

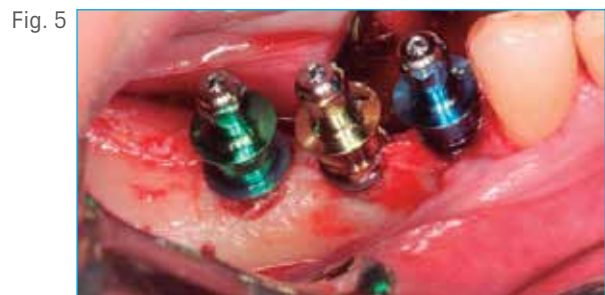

Fig. 5 Implant placement in position 28 [44] a T3® Tapered 4 mm D x 13 mm L, in position 29 [45] a T3 Short Implant 5 mm D x 5 mm L, in position 30 [46] a T3 Short implant 6 mm D x 5 mm L. After using the dense bone tap, 50 Ncm of insertion torque was registered.

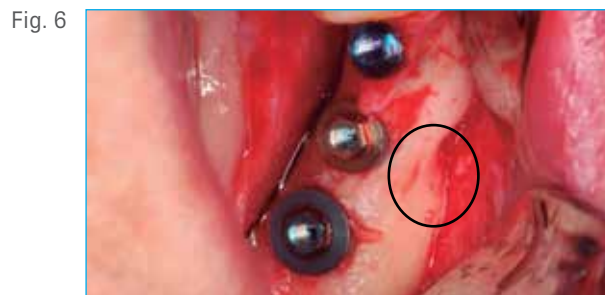
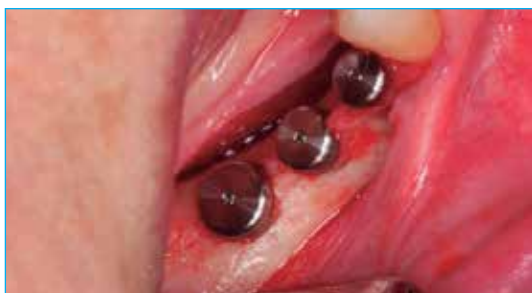
Fig. 6 Occlusal view of the implants, observe the vicinity of where the mental nerve exits.

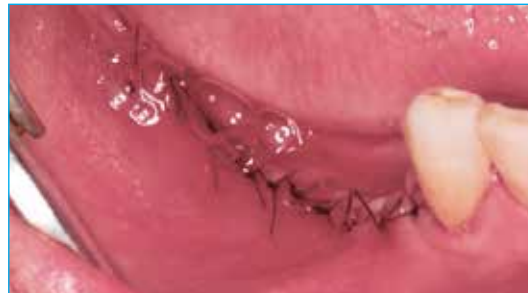Clinical Case

Fig. 7



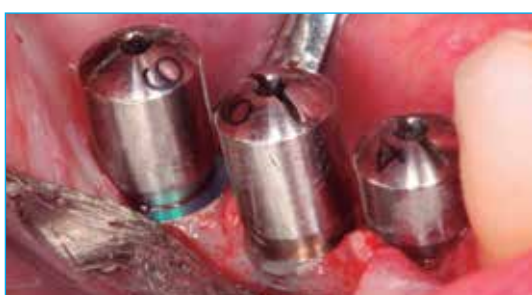All three implants covered with their corresponding cover screws.

Fig. 8



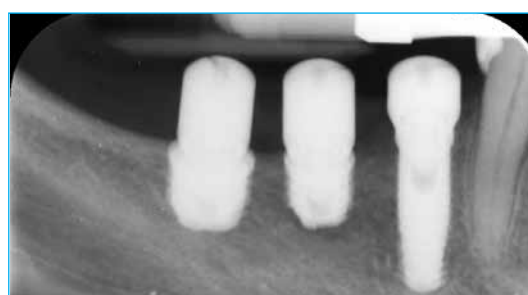Sutures for submerged healing.

Fig. 9



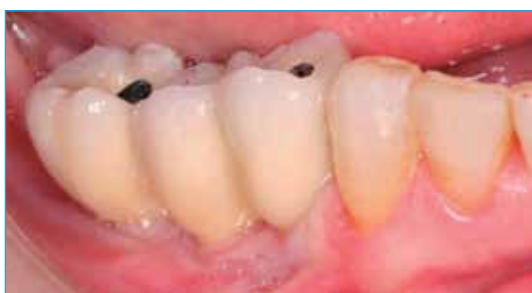Second stage surgery after 3 months of healing. Connection of the healing abutments, with platform switching of the 5 and 6 mm diameter implants to aid in crestal bone preservation.

Fig. 10



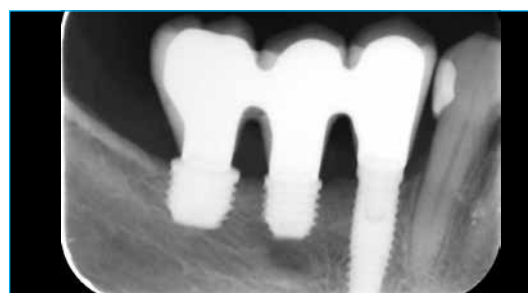
Radiographic control at 3 months.

Fig. 11



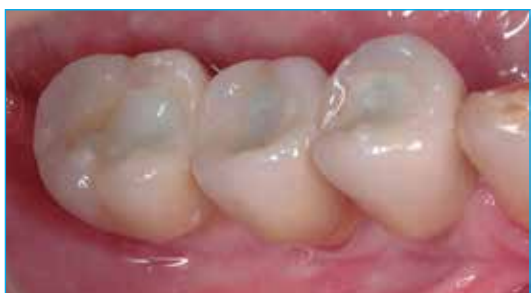Delivery of the final screw-retained bridge 6 months after implant placement.

Fig. 12



Radiograph at final prosthesis placement.

Fig. 13



Occlusal view of the final metal-ceramic screw-retained three-unit bridge after sealing the screw-access holes 6 months post-surgery.

Francisco J. Enrile de Rojas, MD, DDS[†]



Dr. Enrile received his medical degree from the University of Seville, Spain in 1989 and his dental degree from the University of Oviedo (Spain) in 1995. He completed his masters degree in Periodontology and Osseointegration at the same university in 1997. He is member of the Spanish Society of Periodontology (SEPA) and has a private clinic with a training center in Huelva (Spain) dedicated exclusively to Periodontology and Implants.

[†]The contributing clinician has a financial relationship with Zimmer Biomet Dental resulting from speaking engagements, consulting engagements, and other retained services.