

Restoration of a resorbed maxillary right posterior quadrant with short and long implants

Kai Fischer, DMD[†], Germany

The 50-year-old male presented with moderate to severe periodontitis and multiple missing posterior teeth. The radiographic examination revealed reduced vertical bone height in the right maxilla but sufficient bone width. The treatment plan developed included periodontal treatment with some extractions, implant placement in all four quadrants, and supportive periodontal therapy. The right quadrant included placement of a short implant in the first molar region and a longer implant in the first premolar region.

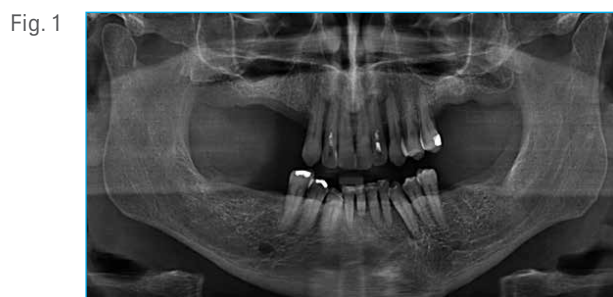

Fig. 1 Preoperative radiograph, showing limited bone height in the maxillary posterior quadrants.

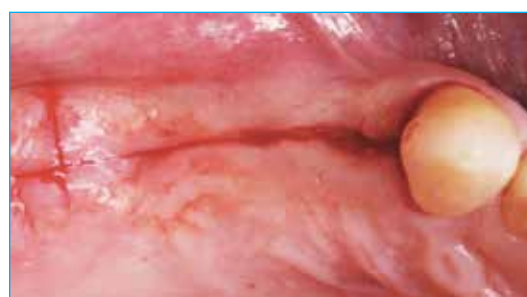

Fig. 2 Incision and flap design included a small t-shaped incision for better access without releasing into the vestibule.

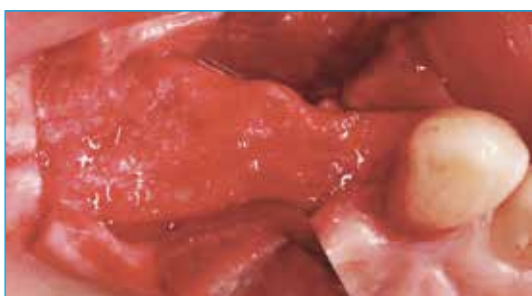

Fig. 3 Clinical view after flap elevation revealing a wide ridge, especially in the posterior area.

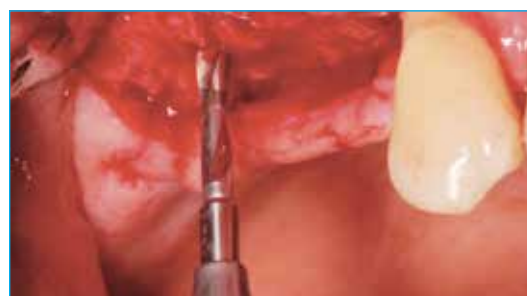

Fig. 4 Initial preparation osteotomy with the 2 mm diameter Twist Drill.

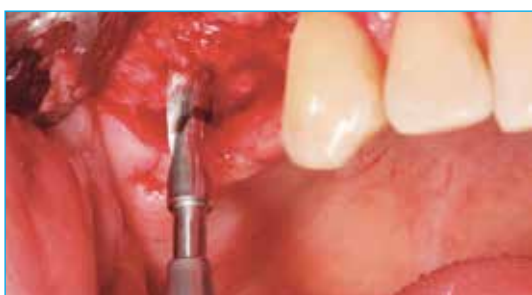

Fig. 5 Widening the osteotomy with the next drill in the recommended protocol (3.25 mm diameter Twist Drill).

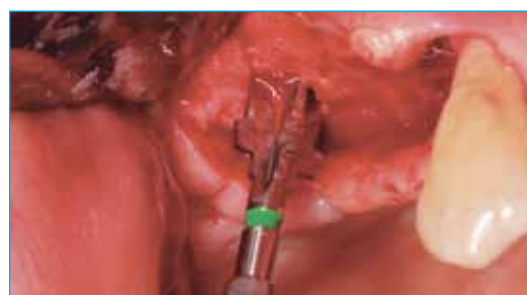

Fig. 6 Finishing the site preparation with the final Flat Bottom Shaping Drill for a 6 mm D x 6 mm L implant.

Clinical Case

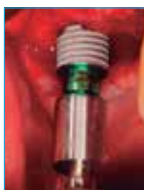


Fig. 7

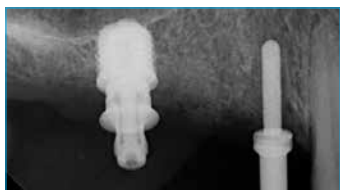


Fig. 8

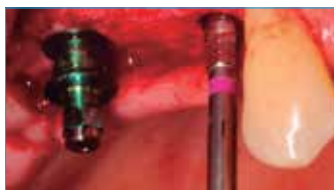

Fig. 9

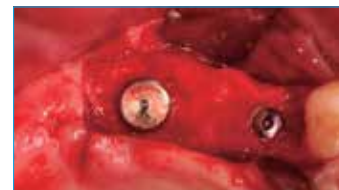

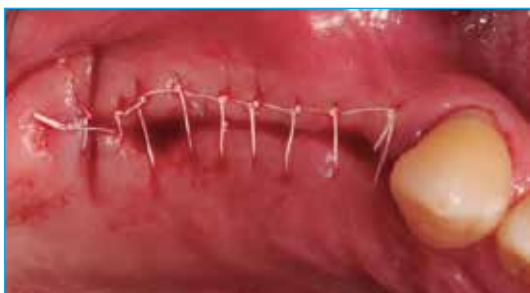Fig. 10

Fig. 7. T3® Short Implant (6 mm D x 6 mm L) placement with the handpiece connector.

Fig. 8. Radiograph of the T3 Short Implant in place. Note the sinus cortical engagement.

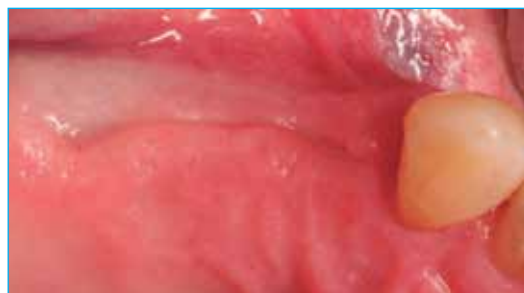Figs. 9, 10. T3 Tapered Implant (4 mm D x 11.5 mm L) placed in the maxillary right first premolar position.

Fig. 11



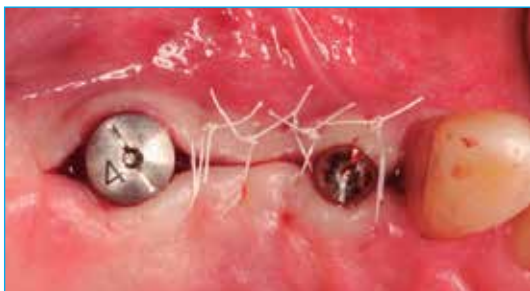Continuous interlocking sutures.

Fig. 12



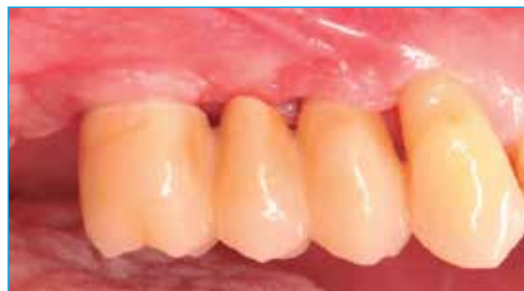Complete healing after 4 months.

Fig. 13



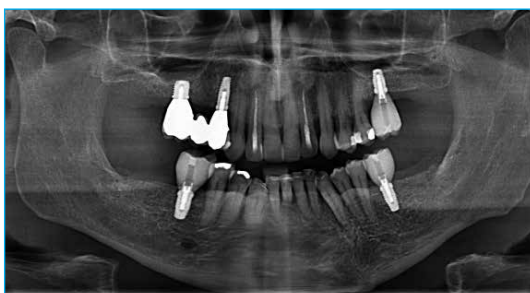Sutures around the healing abutments after second-stage surgery. Note the adequate width of keratinized attached gingiva.

Fig. 14



Definitive restoration in place 6 months post-surgery.

Fig. 15



Final radiograph at the time of insertion of the definitive prosthesis.

Kai Fischer, DMD[†]



Dr. Fischer graduated in dentistry in 2009 and received his title "Dr. med. dent" in 2011. Between 2010–2012, he was working as a Clinical Assistant Professor at the Department of Periodontology, University of Würzburg, Germany where he obtained further training in periodontology and implant dentistry. In 2013, he became a Specialist in Periodontics. From 2013–2016 he was a Honorary Research Associate & Clinical Teaching lecturer at UCL Eastman Dental Institute, London, UK and at the University Witten/Herdecke. Currently he works at Drs. Schütz/Tawassoli, Würzburg - Private dental practice.

[†]The contributing clinician has a financial relationship with Zimmer Biomet Dental resulting from speaking engagements, consulting engagements, and other retained services.