

## Short implant replacing the first molar in an extremely resorbed posterior maxilla

Francesco Amato, Italy, MD, DDS, PhD<sup>†</sup>, Italy

The 50-year-old male patient was missing the premolars and the first molar in the left maxilla. The clinical and radiographic findings were two hopeless premolar roots and a severely resorbed alveolar crest due to sinus pneumatization. The treatment plan included placement of a standard length immediate implant in the first premolar region and a short implant in the molar region splinted in a three-unit bridge.

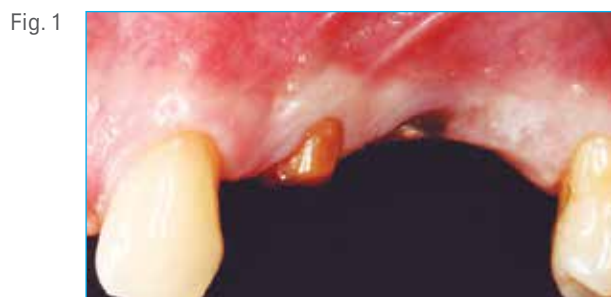

Fig. 1

Preoperative clinical photograph showing the hopeless premolar roots.

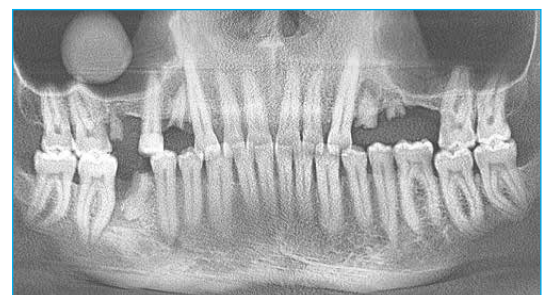

Fig. 2

Preoperative radiograph. Note the severely resorbed alveolar crest and the sinus pneumatization.

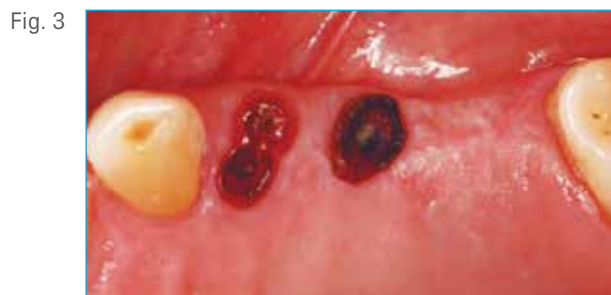

Fig. 3

Occlusal view after the roots were extracted.

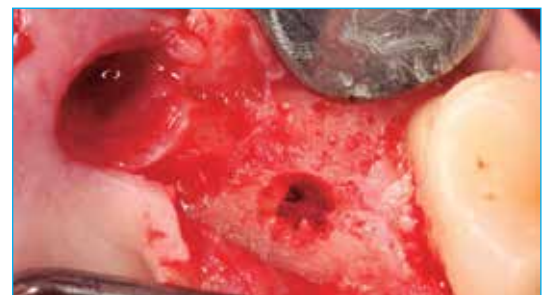

Fig. 4

Osteotomy preparation. The molar site was prepared with a small 2 mm diameter drill followed by a convex osteotome to push the cortical bone and slightly elevate the sinus membrane.

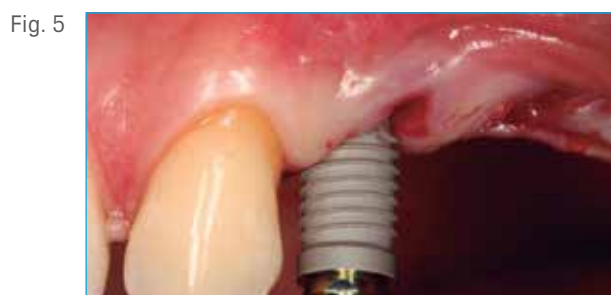

Fig. 5

A standard size 11.5 mm L x 5 mm D T3® with DCD® Tapered Implant was inserted in the first premolar extraction site.

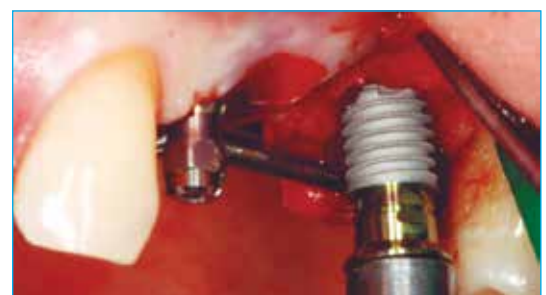

Fig. 6

A 5 mm D x 6 mm L T3 Short Implant with DCD was inserted in first molar site.

Clinical Case

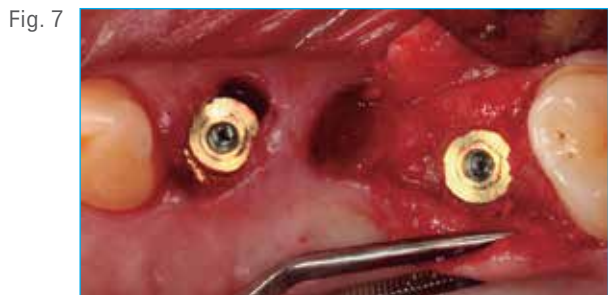

Fig. 7 Occlusal view of the two 5 mm diameter implants.

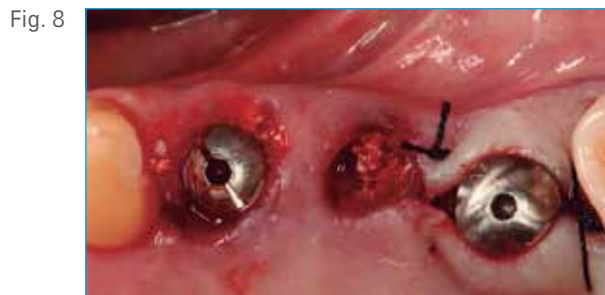

Fig. 8 Healing abutments in place for unsubmerged healing. The extraction sites are filled with Endobon® Xenograft Granules.

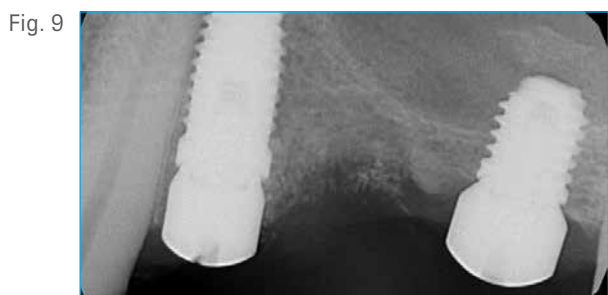


Fig. 9 Postoperative radiograph. Note the T3® Short Implant of 6 mm length partially invading the sinus.

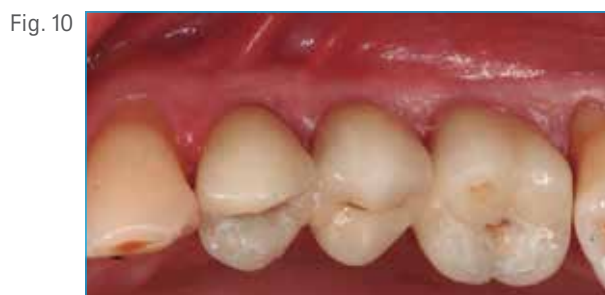

Fig. 10 Occlusal view of the definitive three-unit bridge 6 months post-op.

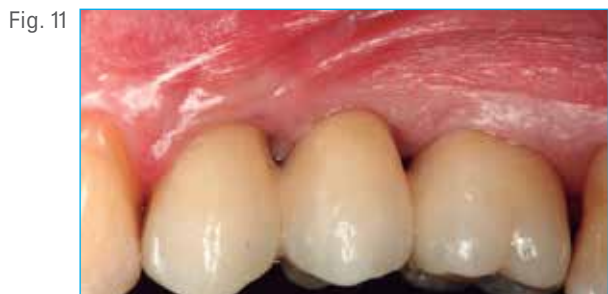

Fig. 11 Buccal view of the definitive prosthesis 6 months post-op.



Fig. 12 Final radiograph 6 months post-op. Note the bone growth inside the sinus around the apex of the T3 Short Implant.

Francesco Amato, MD, DDS, PhD<sup>†</sup>



Dr. Francesco Amato completed his MD degree at the University of Catania, Italy in 1991. In 1992–1993 he completed a one year full time Advanced Program for International Dentists in Periodontics at New York University College of Dentistry followed by two years full time Advanced Program for International Dentists in Implant Dentistry at New York University College of Dentistry, 1993–1995. He completed his continuing Education Program in Implant Dentistry at New York University College of Dentistry, 1994–1995. He received his Ph.D. Biopharmaceutical Microbiology at the University of Catania, Italy, 1994–1997. He has published numerous articles in international journals; is a lecturer in National and International Conferences and Courses. He is in his private practice specializing in Periodontics and Implant Dentistry in Catania, Italy, and is a Clinical Professor in the Master of Periodontology at Universitat Internacional de Catalunya, Spain, a Visiting Professor in the Department of Periodontology at Columbia University, New York, and an International lecturer for the Continuing Dental Education at New York University, New York.

<sup>†</sup>The contributing clinician has a financial relationship with Zimmer Biomet Dental resulting from speaking engagements, consulting engagements, and other retained services.