

Restoration of resorbed mandibular right posterior quadrant with short implants after horizontal bone augmentation

Piotr Majewski, Ph.D, DMD[†], Poland

The 54-year-old female patient was missing teeth numbers 29, 30 and 31 [45, 46 and 47]. The clinical and radiographic studies revealed reduced bone height (less than 6 mm) in the molar region with insufficient ridge width for a wide implant. The treatment plan consisted of horizontal ridge augmentation with an autogenous bone block and xenograft to increase width to allow for the replacement of the three missing teeth with short implants.

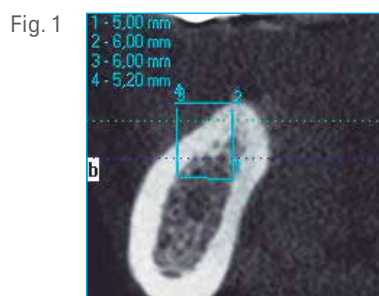


Fig. 1 Cone Bean CT scan before the bone graft. A thin alveolar ridge is observed with insufficient width for placement of a 5 mm diameter implant.

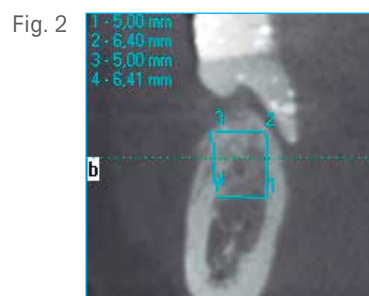

Fig. 2 Cone Bean CT scan after the bone augmentation. The implant site width now allows for the placement of a 5 mm diameter implant.

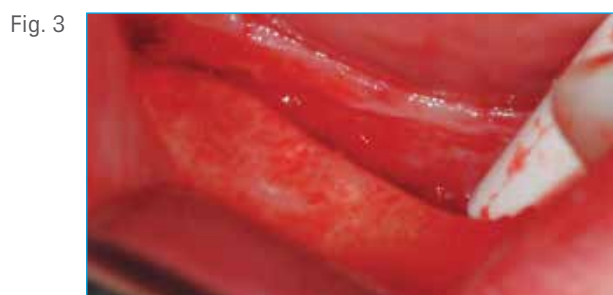


Fig. 3 Exposition of the narrow crest in the posterior right mandible prior to the bone augmentation procedure.

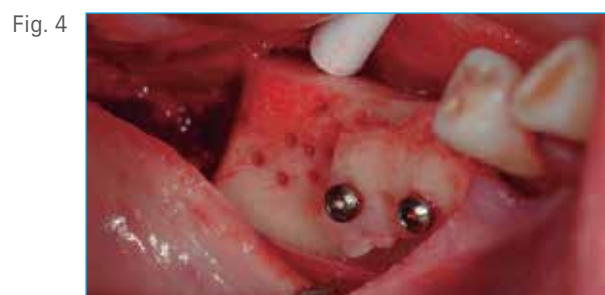

Fig. 4 Autogenous bone block harvested from the retro-molar area and fixed with two mini-screws in tooth positions 29 and 30 [45 and 46].

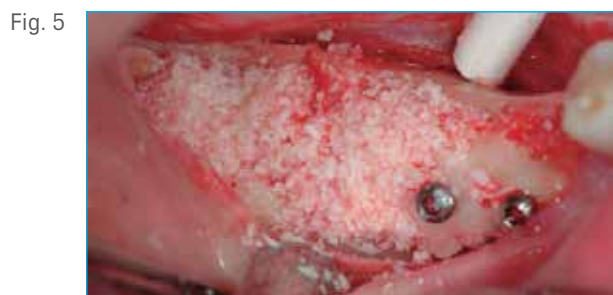

Fig. 5 The bone block and the distal zones are covered with particulated xenograft.

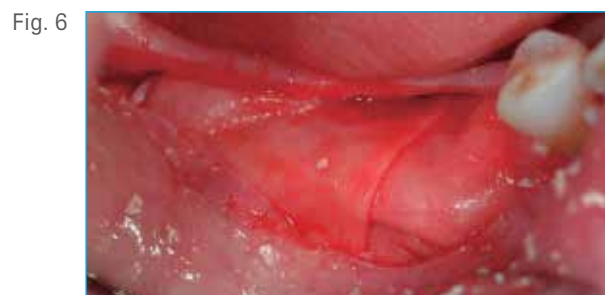

Fig. 6 The bone grafts are covered by two resorbable collagen membranes.

Clinical Case

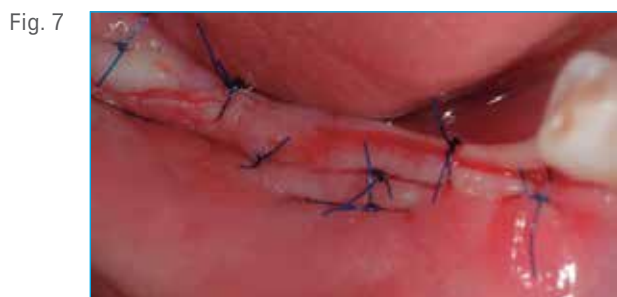

Fig. 7 Suturing after horizontal augmentation procedure. Note the primary closure achieved.

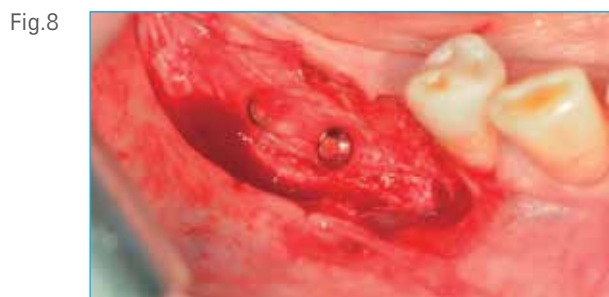

Fig. 8 Reopening of the grafted sites after 4 months of healing. The bone block has been biologically incorporated. Optimal ridge thickness has been achieved for placement of 5 mm diameter implants.

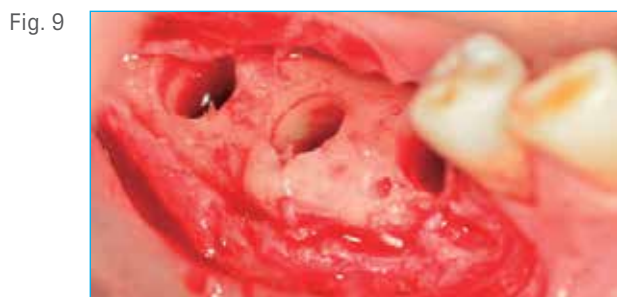

Fig. 9 Osteotomies in the regenerated sites following the drilling protocol of the T3® Short Implant system.

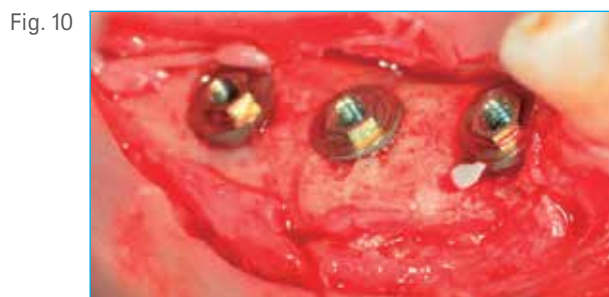

Fig. 10 Three T3 Short Implants of 5 mm diameter x 5 mm length were placed.

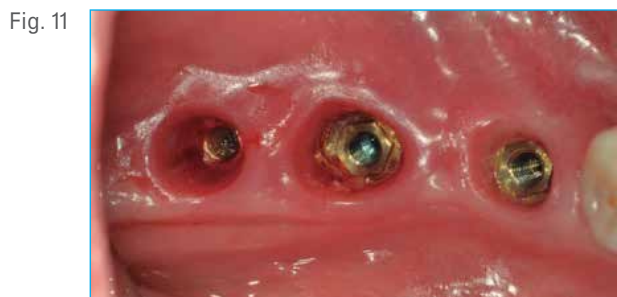

Fig. 11 4 months after placement the implants are osseointegrated and ready for the prosthetic phase.

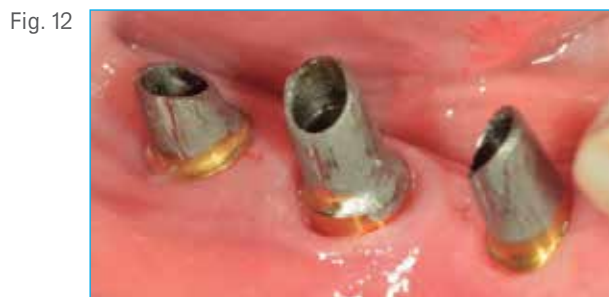

Fig. 12 Three Gingil-Hue® Abutments adjusted by the laboratory technician are placed and screwed into the implants with Gold-Tite® Screws torqued at 35 Ncm.

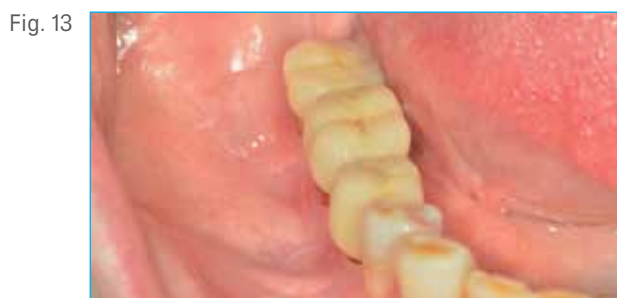

Fig. 13 Final cement-retained bridge in place 9 months after the augmentation surgery and 5 months after implant placement.

Piotr Majewski, Ph.D, DMD[†]



Dr. Majewski is a Graduate of the Faculty of Medicine/Department of Dentistry at the Jagiellonian University Medical College, Cracow, Poland. He completed his supplementary studies at the University of Melbourne, Australia and trainings at different implant centers in USA, Sweden, Italy, Switzerland and Germany. He received the Specialist degree in Dental Surgery. Since 2004, He is Head of Department of Implantology at the Institute of Dentistry at the Jagiellonian University Medical College in Cracow, Poland and Head of the CEIA (Central European Implant Academy). He is a lecturer at the Implant Continuum Education Program at New York University College of Dentistry and an international speaker and faculty member of the Zimmer Biomet Institute.

[†]The contributing clinician has a financial relationship with Zimmer Biomet Dental resulting from speaking engagements, consulting engagements, and other retained services.