

## Replacement of an implant due to peri-implantitis in the maxillary molar region with delayed placement of a short implant and simultaneous grafting

Ronnie J. Goené, DMD<sup>†</sup> and Alwin C.L. van Daelen, DMD<sup>†</sup>, The Netherlands

The patient presented with a failing implant due to peri-implantitis in the maxillary first molar position and a failing natural premolar tooth with periodontitis. Clinical and radiographic examination revealed the presence of very reduced bone height in the molar region, which would enable the placement of only a short implant. A treatment plan was developed where a short implant was placed in tooth position 3 [16] with simultaneous grafting in a two-stage approach. A longer implant was to be placed in the premolar site. After a 4-month healing period, two single definitive crowns were delivered to the patient.

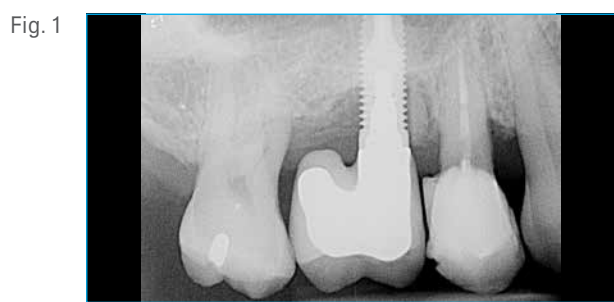


Fig. 1

Radiograph showing the infected implant in the molar region and a failing premolar tooth.

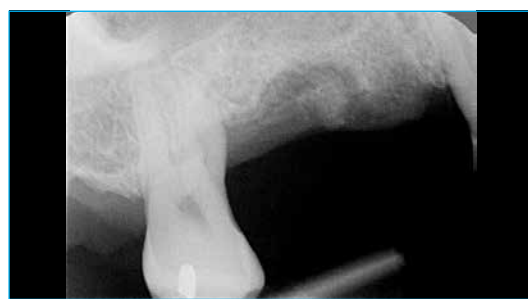

Fig. 2

Preoperative radiograph 4 months after explantation of the failed implant. Note the limited remaining bone height in the molar region.

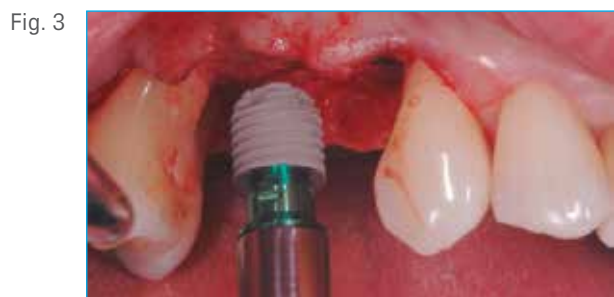

Fig. 3

Placement of a T3® Short Implant (6 mm D x 5 mm L) in position 3 [16] and a longer T3 Parallel Walled Implant (4 mm D x 10 mm L) in tooth position 4 [15].

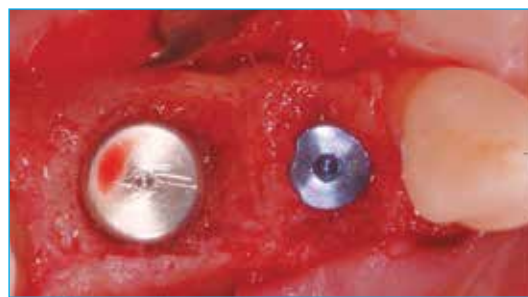

Fig. 4

Occlusal view of the two implants in place with their corresponding cover screws for submerged healing.



Fig. 5

Grafting of the remaining bone defect around the T3 Short Implant with Endobon® Xenograft Granules.

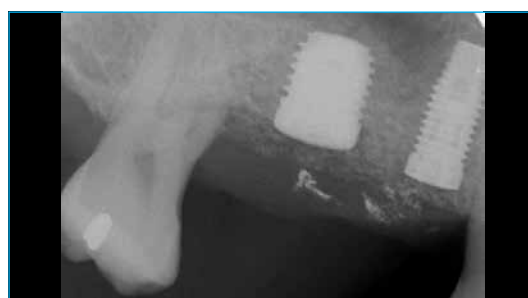
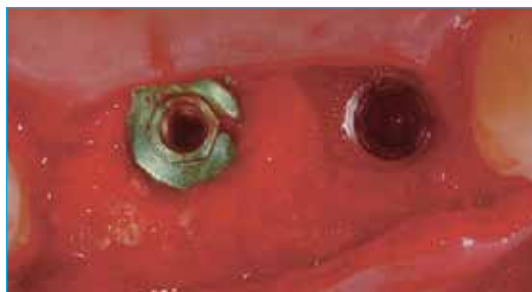
Fig. 6

Radiograph after implant placement, grafting and sutures.

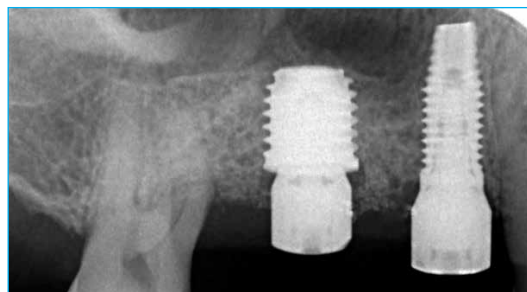Clinical Case

Fig. 7



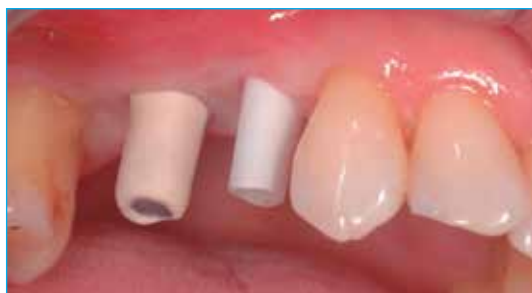Re-opening 4 months after surgery.

Fig. 8



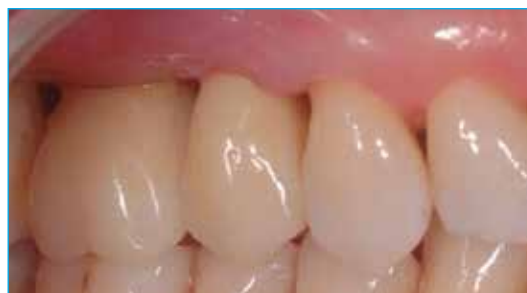Radiograph at second-stage surgery 4 months post-op. Manual platform switching was done on the T3® Short Implant by placing a 5 mm diameter healing abutment on the 6 mm diameter implant.

Fig. 9



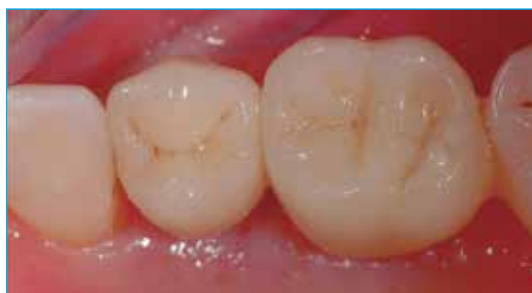Two definitive abutments in place 4.5 months after implant placement.

Fig. 10



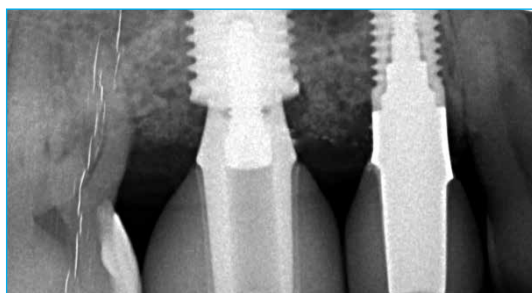
Final cemented single-unit premolar and molar crowns.

Fig. 11



Occlusal view of the definitive crowns.

Fig. 12



Radiograph of the definitive restorations taken at 4.5 months post-implant placement.

**Ronnie J. Goené, DMD<sup>†</sup>**



Dr. Goené is an Associate Professor in the Department of Oral and Maxillofacial Surgery/Pathology of the Academic Center for Dentistry Amsterdam and VU University Medical Center. He lectures extensively on implant aesthetic dentistry. He maintains a private clinic limited to

implantology in Amsterdam, the Netherlands.

**Alwin C.L. van Daelen, DMD<sup>†</sup>**



Dr. van Daelen is a Clinical Assistant Professor at the Department of Oral and Maxillofacial Surgery/Oral Pathology, Academic Center for Dentistry Amsterdam and VU University Medical Center. He maintains a renowned private and referral practice in Amsterdam, The

Netherlands, treating restorative and aesthetic cases.

<sup>†</sup>The contributing clinicians have financial relationships with Zimmer Biomet Dental resulting from speaking engagements, consulting engagements, and other retained services.